

Multiple Primary Oesophageal Tumours

UCTN

The importance of long-term follow-up of oesophageal cancer has increased due to improved survival [1] and increased incidence. We describe a patient whose case raises a number of important issues regarding surveillance.

A 72-year-old woman presented with dysphagia and weight loss. She had undergone oesophagectomy for squamous-cell carcinoma (stage IIB) 41 years previously. She was given a guarded prognosis at that time, but lived a full life, becoming pregnant later that year. She remained well until this second presentation. Upper gastrointestinal endoscopy revealed an ulcerated mass proximal to the anastomosis, which was found to be a moderately differentiated adenocarcinoma (Figure 1). Abdominal computed tomography showed liver metastases. The patient completed courses of chemotherapy and radiotherapy and survived for a further 3 years.

This case of adenocarcinoma of the oesophageal remnant, arising 41 years after resection of a squamous-cell carcinoma, raises several points. Firstly, there is free cardia and proximal stomach reflux from the gastric remnant following resection. The pH of the stomach reverts to normal in 81.5% of patients 3 years after oesophageal replacement by transthoracic elevation of the stomach [2]. Indeed, there is an increased risk of gastric and oesophageal cancer after partial gastrectomy, perhaps caused by prolonged nitrosamine exposure [3]. As a result of there being a common compartment, the pH and the nitrosamine exposure in the oesophageal remnant and the gastric remnant are similar. Therefore, all long-term survivors of oesophageal cancer are at risk of dysplasia and carcinoma of the oesophageal remnant. Gender may influence long-term survival and a significant survival advantage in women under the age of 49

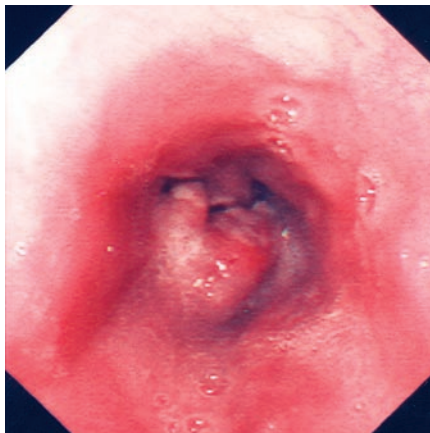


Figure 1 Endoscopy revealed a moderately differentiated adenocarcinoma, with overlying ulcerated squamous mucosa, proximal to the anastomosis.

years has been reported [4], perhaps attributable to the hormonal milieu. In this patient, pregnancy may have conferred an additional advantage in terms of survival.

Treatment with multimodal therapy can predispose to neoplasia. Chemotherapy may induce metaplasia and immunohistochemical studies of patients receiving neoadjuvant chemoradiotherapy have reported an increase in tumour-associated macrophages expressing vascular endothelial growth factor (VEGF), which may potentially stimulate tumour angiogenesis [5].

In conclusion, patients need surveillance and advice on the long-term risks after oesophageal resection. Multimodal treatment may exacerbate this risk.

P. Naughton, M. Atie, E. Leen, T. N. Walsh

¹ Department of Surgery, James Connolly Memorial Hospital, Dublin, Ireland

² Department of Pathology, James Connolly Memorial Hospital, Dublin, Ireland.

References

- Walsh TN, Noonan N, Hollywood D et al. A comparison of multimodal therapy and surgery for esophageal adenocarcinoma. *N Engl J Med* 1996; 335: 462–466
- Gutschow C, Collard JM, Romagnoli R et al. Denervated stomach as an esophageal substitute recovers intraluminal acidity with time. *Ann Surg* 2001; 233: 509–514
- Sherman DJ, Arnott SJ, Finlayson NDC, Pearson JG. Carcinoma of the oesophagus after gastric surgery. *Lancet* 1971; 1: 19–20
- Badwe RA, Patil PK, Bhansali MS et al. Impact of age and sex on survival after curative resection for carcinoma of the esophagus. *Cancer* 1994; 74: 2425–2429
- McDonnell CO, Bouchier-Hayes DJ, Harmey J et al. The effect of neoadjuvant chemoradiotherapy on angiogenesis in oesophageal cancer. *Br J Surg* 2003; 90: 1373–1378

Corresponding Author

T. N. Walsh

Academic Centre
James Connolly Memorial Hospital
Blanchardstown
Dublin 15
Ireland
E-mail: tnwalsh@indigo.ie